

The American Journal of Sports Medicine

<http://ajs.sagepub.com/>

Cyclic Loading of 3 Achilles Tendon Repairs Simulating Early Postoperative Forces

Steven J. Lee, Michael J. Sileo, Ian J. Kremenec, Karl Orishimo, Simon Ben-Avi, Stephen J. Nicholas and Malachy McHugh

Am J Sports Med 2009 37: 786 originally published online February 9, 2009

DOI: 10.1177/0363546508328595

The online version of this article can be found at:

<http://ajs.sagepub.com/content/37/4/786>

Published by:



<http://www.sagepublications.com>

On behalf of:

American Orthopaedic Society for Sports Medicine



Additional services and information for *The American Journal of Sports Medicine* can be found at:

Email Alerts: <http://ajs.sagepub.com/cgi/alerts>

Subscriptions: <http://ajs.sagepub.com/subscriptions>

Reprints: <http://www.sagepub.com/journalsReprints.nav>

Permissions: <http://www.sagepub.com/journalsPermissions.nav>

>> [Version of Record](#) - Mar 31, 2009

[OnlineFirst Version of Record](#) - Feb 09, 2009

[What is This?](#)

Cyclic Loading of 3 Achilles Tendon Repairs Simulating Early Postoperative Forces

Steven J. Lee, MD, Michael J. Sileo,* MD, Ian J. Kremenic, ME, Karl Orishimo, MS, Simon Ben-Avi, PhD, Stephen J. Nicholas, MD, and Malachy McHugh, PhD
From the Nicholas Institute of Sports Medicine and Athletic Trauma, Lenox Hill Hospital, New York, New York

Background: Accelerated rehabilitation has been advocated after Achilles tendon repair, but it produces significant forces at the repair site.

Hypothesis: Stresses applied to the repaired Achilles tendon simulating postoperative forces may exceed the strength of some repairs.

Study Design: Controlled laboratory study.

Methods: Fifteen Achilles tendons were incised 4 cm proximal to the calcaneal insertion, then were repaired using either a percutaneous, 4-strand Krackow, or an epitendinous augmented 4-strand Krackow technique. Tendons were cyclically loaded to 1000 cycles each at 100, 190, and 369 N. The number of cycles to initial gapping, 5-mm gapping, and total failure were compared using Mann-Whitney *U* tests with adjustments for multiple comparisons.

Results: Gap resistance was significantly greater for augmented Krackow repairs (2208 cycles to initial gapping) versus nonaugmented repairs (502 cycles, $P = .024$) and for nonaugmented Krackow repairs versus percutaneous repairs (5 cycles, $P = .024$). All percutaneous repairs failed during the 100-N cycling (102 ± 135 cycles). All nonaugmented Krackow repairs failed during the 190-N cycles (total cycles to failure: 1268 ± 345). All augmented Krackow repairs were intact (no gapping) after the 190-N cycles. Four failed during 369-N cycling (total cycles to failure, 2017 ± 11), and 1 remained intact for 3000 cycles.

Conclusion: Epitendinous cross-stitch weave augmentation of Achilles tendon repairs significantly increased repair strength and gap resistance.

Clinical Relevance: Epitendinous cross-stitch weave augmentation of Achilles tendon repairs may better allow for early stretching and ambulation after Achilles tendon repair.

Keywords: Achilles rupture; open repair; percutaneous repair; Achilles rehabilitation

Numerous techniques have been advocated for the surgical treatment of Achilles tendon ruptures without a clear consensus as to the optimal method.[†] Controversy still exists as to whether percutaneous or open methods of surgical repair provide better clinical results. To further complicate this, both open and percutaneous methods have been described using multiple surgical techniques. The success of these various repairs depends on what outcomes measures are used and can be less than ideal.

*Address correspondence to Michael J. Sileo, MD, Lenox Hill Hospital, 130 East 77th Street, New York, NY 10021 (e-mail: mikesileo@hotmail.com).

Presented at the 32nd annual meeting of the AOSSM, Hershey, Pennsylvania, June 2006.

No potential conflict of interest declared.

The recent trend has been to accelerate the rehabilitation protocol after Achilles tendon repair. This includes earlier range of motion, weightbearing, and strengthening, as well as shorter immobilization times and faster return to sports. However, these accelerated protocols have not been based on strong basic science. Without this knowledge, it is difficult to establish sound guidelines or to tell whether existing guidelines are safe.

On the basis of this clinical trend for accelerated rehabilitation after surgical repair, there appears to be a need for stronger, more gap-resistant repairs. Epitendinous suture augmentation has been shown to significantly increase gap resistance and overall strength in Achilles tendon repairs when tested to failure.¹⁶ The purpose of this study was to identify the most effective suture repair technique for Achilles tendon repair by subjecting these repairs to cyclic loads, as would be experienced in the postoperative

[†]References 2, 7, 12, 13, 15, 20, 21, 24, 26, 28, 30.

period. It was hypothesized that epitendinous suture augmentation of Achilles tendon repair would improve the ability of repairs to withstand cyclic loading. To our knowledge, the effect of this technique has not been previously studied in Achilles tendons.

MATERIALS AND METHODS

Fifteen fresh-frozen, human, male cadaveric Achilles tendons with the calcaneus attached were thawed and harvested. The average age of the specimens was 39 years (range, 32-45). The Achilles tendon was sharply transected 4 cm proximal to the tendon insertion. The specimens were kept moist with normal saline at room temperature throughout the testing.

The tendons were repaired by 1 of 3 repair techniques. The first group consisted of a simulated percutaneous repair technique, the technique being similar to that described for the Achillon (Integra Life Sciences, Plainsboro, New Jersey) system (Figure 1). The actual repair was performed using No. 2 Ethibond sutures (Ethicon Inc, Somerville, New Jersey) with the skin removed and therefore represented the optimal surgical fixation possible for this technique. The second group consisted of a nonaugmented 4-stranded Krackow technique with No. 2 Ethibond sutures (Ethicon Inc) tied with 5 simple half-hitches. The final group consisted of a 4-stranded Krackow repair augmented with a cross-stitch epitendinous weave (Figure 2). The augmentations were performed using 0 PDS suture (Ethicon Inc) so that the suture grabbed not only the epitendon but also the tendon tissue approximately 2.5 cm away from the rupture site. Both the Krackow and epitendinous weave were tied with 5 simple half-hitches after suture passage.

The specimens were secured onto a materials testing system (MTS Systems Corp, Eden Prairie, Minnesota) by drilling a hole in the calcaneus in line with the tendon and inserting into it a large bolt, nuts, and washers. This was then coated with polymethylmethacrylate bone cement (Howmedica International S de RL, Limerick, Ireland) to eliminate any movement at the hardware-bone interface. The Achilles tendon was secured proximally onto a tendon clamp and the remaining tendon rolled around the clamp to minimize stress on the clamp-tendon interface and eliminate slippage. The specimens were secured onto the MTS by clamping onto the head of the bolt on one side and onto the tendon clamp on the other side, with the direction of pull parallel to the longitudinal axis of the tendon.

All specimens were subject to a cyclic loading protocol, which consisted of 3 levels. First, each specimen was loaded from 20 to 100 N at 1 Hz for 1000 cycles. If the specimen survived the initial test level, it was subjected to another 1000 cycles from 20 to 190 N. If the specimen withstood this level without failure, another 1000 cycles from 20 to 369 N were applied. The forces used are based on the following: 20 and 100 N were the lower and upper limits of Achilles tendon force estimated during passive ankle flexion in an isokinetic dynamometer,²³ and 190 and 369 N were the forces estimated in the Achilles tendon

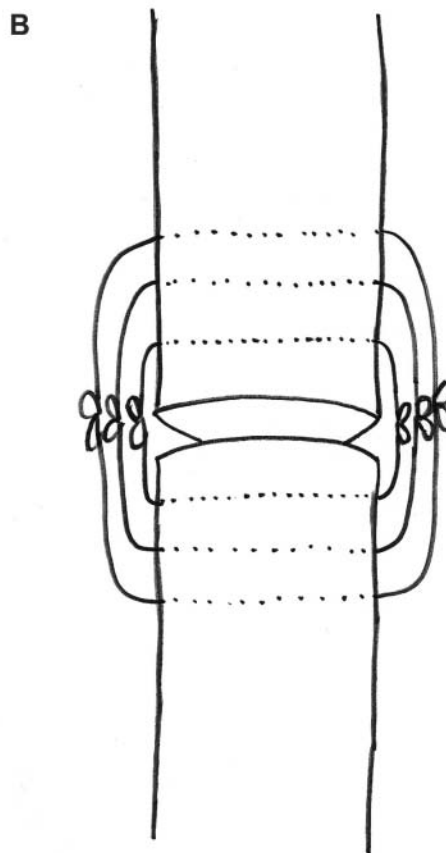
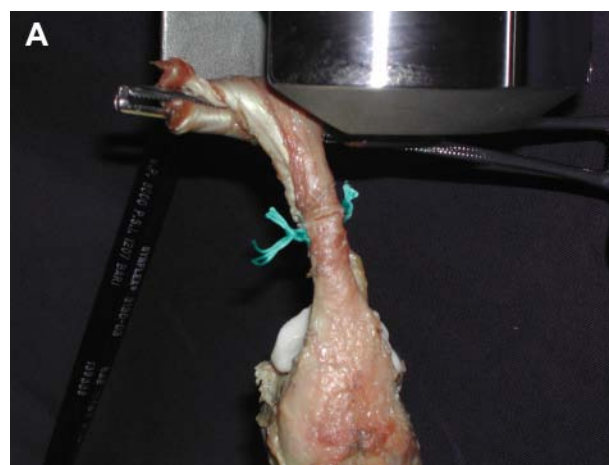


Figure 1. (A) Percutaneous repair of the Achilles tendon. (B) Schematic of percutaneous repair. All knots are tied at the repair site.

during walking in a Cam Walker with and without the use of a 1-inch heel lift, respectively.¹ The frequency of 1 Hz was meant to simulate walking cadence.

Specimens surviving all 3 levels of cyclic loading were then loaded to failure at a rate of 25 mm/s. The number of cycles to initial gapping (defined as any measurable gap formation), 5-mm gapping, and total failure was compared for

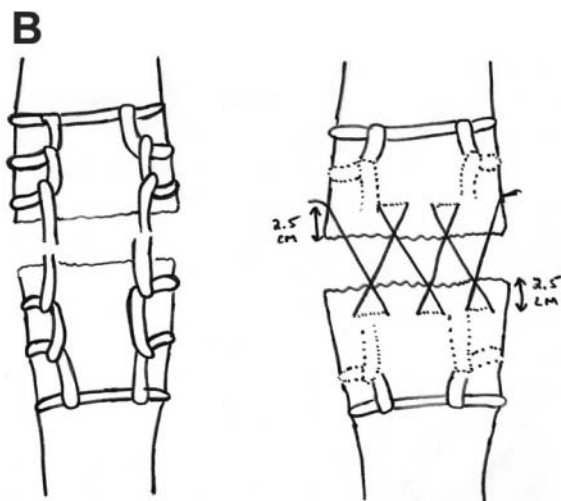
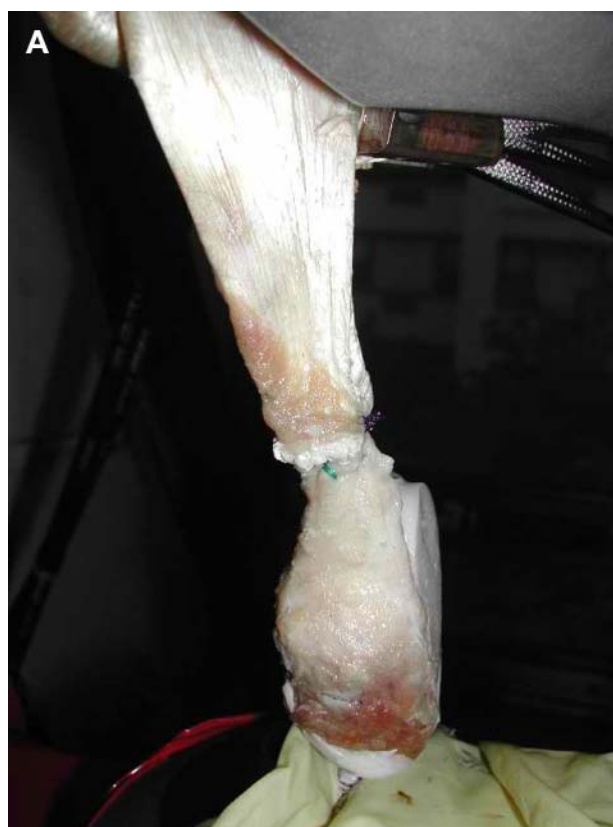

Figure 2. (A) Krackow stitch augmented with epitendinous weave. (B) Schematic of Krackow augmented with epitendinous weave. Left, Krackow stitch run in each end of the ruptured tendon. Right, Epitendinous weave run after the Krackow stitch. The epitendinous weave is passed through the tissue 2.5 cm from the torn end of the tendon on each side of the repair.

each type of repair. Gapping was documented continuously during cyclic testing using digital calipers (Scienceware Vernier Direct Reading Calipers model H13415-0000, Bel-Art Products, Pequannock, New Jersey) and was measured at the aspect of the repair with the greatest gap formation.

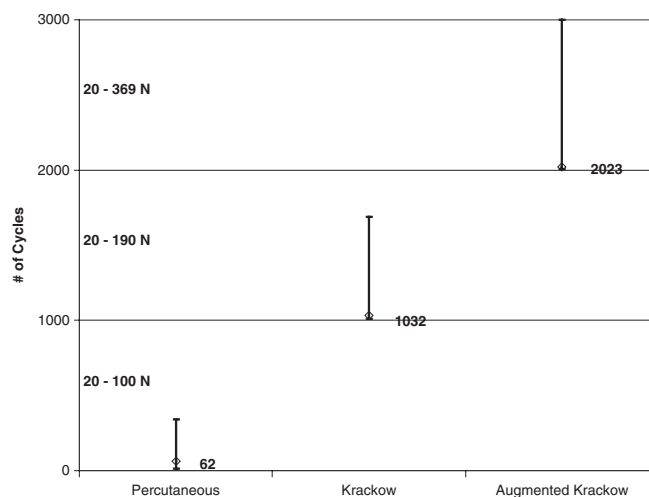


Figure 3. Median and range (error bars) for the number of cycles to total failure for the 3 different repair techniques. Note the different loads employed during each part of the testing. Median cycles for each technique are also shown in the text. Effect of repair technique ($P = .002$): percutaneous versus Krackow, $P = .024$; Krackow versus augmented Krackow, $P = .024$; and percutaneous versus augmented Krackow, $P = .024$.

Total failure was defined as greater than 1-cm gapping or a precipitous drop of measured force.

The Kruskal-Wallis test was used to assess if there was an effect of repair technique on the number of cycles to initial gapping in the repair, 5-mm gapping, and total repair failure. If an effect was noted, post hoc Mann-Whitney tests (with Bonferroni corrections for multiple comparisons) were performed to assess differences between the different techniques. An α level of .05 was assumed to be statistically significant.

RESULTS

Percutaneous repairs all failed during cyclic loading at 100 N, while nonaugmented Krackow repairs all failed during cyclic loading at 190 N (Figure 3). Four augmented repairs failed during cyclic loading at 369 N, while 1 survived the entire cyclic loading protocol, subsequently failing at 550 N.

Kruskal-Wallis testing showed that for all variables of interest (number of cycles to initial gapping, 5-mm gapping, and total failure), there was an effect of repair ($P = .002$) (Table 1). Post hoc testing (Mann-Whitney) revealed that for all 3 measures, the augmented repairs were stronger than both the Krackow and the percutaneous repairs ($P < .05$) (Table 1). Additionally, the Krackow repairs were stronger than the percutaneous repairs ($P = .024$).

Mode of failure for the percutaneous repairs was suture pull through the tendon. For nonaugmented Krackow repairs, gapping appeared to occur initially due to suture pull through the tendon and total failure due to a combination of suture pull-through and suture breakage. For the augmented

TABLE 1
Number of Cycles to Initial Gap, 5-mm Gap, and Total Failure for the 3 Different Repair Techniques^a

No. of Cycles	Percutaneous	Krackow	Augmented Krackow
Initial gap	5.0 (1-9)	502 (90-1070) ^b	2208 (2005-3000) ^{b,c}
5-mm gap	22 (9-35)	741 (200-1206) ^b	2213 (2006-3000) ^{b,c}
Total failure	102 (13-340)	1268 (1010-1690) ^b	2213 (2007-3000) ^{b,c}

^aNumbers reported are mean (range).

^bIndicates greater than percutaneous repair, $P = .024$.

^cIndicates greater than nonaugmented Krackow repair, $P = .024$.

repairs, mode of failure for all specimens was suture breakage, with the epitendinous sutures breaking first.

DISCUSSION

Achilles tendon ruptures are common injuries, for which surgical repair is becoming an increasingly accepted treatment.[‡] The type of surgical treatment, however, continues to be controversial. Not only are there disparities between surgeons using either percutaneous versus open repairs, but there are several described techniques within each category.

Proponents of percutaneous repairs cite decreased incidence of wound complications, infections, operative time, and better cosmetic appearance. Initial reports have shown possible sural nerve damage,^{3,5,18} while more recent reports seem to have minimized this complication.^{10,17,19,29} Various techniques have been employed to perform percutaneous repairs. One of the most common techniques used is the Achillon system, which places 3 horizontal sutures onto each side of the disrupted Achilles tendon, while the knots are tied at the repair site. However, the greatest potential downside to percutaneous repairs is the strength of the repairs, shown by some authors to be as much as 50% weaker than open repairs.¹¹

Advocates of the more traditional open-type repair cite increased repair strength with acceptable wound complications and cosmesis. Again various surgical techniques have been described. Krackow et al¹⁵ described a commonly used locking-loop technique and found it to have a pull-out strength of 392 N via a one-time load-to-failure study. Watson et al²⁸ found their locking-loop technique to be significantly stronger than a Bunnell or Kessler technique. However, failure was determined solely when there was a precipitous drop in the force. We have found in a previous study as well as in this study that a significant amount of gapping occurs before ultimate failure of the repair, and this gapping is decreased when augmented with an epitendinous cross-stitch weave.¹⁶ Greater than 5-mm gapping might be considered just as important of a parameter for clinical failure.¹⁶

Both open and percutaneous repair techniques have been reported to have acceptable clinical results.^{4,6,9,10,25,27} If rerupture is to be considered the major outcome criterion, just about any type of repair or even nonoperative immobilization can be considered acceptable. However, a closer look at outcomes reveals less than acceptable results. For example, Kangas et al¹⁴ placed markers on each side of Achilles tendon repair sites and showed significant separation of the tendon ends during the postoperative period. Further, weakness in end-range plantar flexion has been demonstrated after “successful” Achilles tendon repair and has been attributed to excessive tendon lengthening.²² Whether this is due to a lack of proper tensioning at the time of surgery or progressive tendon lengthening during the postoperative period was not elucidated.

It should not be surprising that tendon lengthening exists after surgery. It has been estimated that with the ankle immobilized in neutral dorsiflexion, the forces across the Achilles tendon are as high as 370 N¹ and as high as 1500 N during normal, unrestricted walking.⁸ It has been shown that even with passive range of motion of the ankle, often performed within weeks of surgery, the forces across the Achilles tendon can approach 400 N.²³

In this study, simulated percutaneous repairs had significantly decreased strength compared with the other 2 repair techniques. All specimens failed within loads that are typically seen with passive range of motion in postoperative therapy. Nonaugmented Krackow repairs were significantly stronger than percutaneous repairs, but all specimens failed with loads comparable to that seen with weightbearing with a 1-inch heel lift. Augmented Krackow repairs were significantly stronger than both the nonaugmented Krackow repairs and the percutaneous group, withstanding loads comparable to weightbearing with a 1-inch heel lift, but not weightbearing without a heel lift.

On the basis of this study, it would not be advisable to start an early range of motion protocol for patients repaired with this percutaneous technique. It appears that nonaugmented Krackow repairs can withstand early range of motion rehabilitation but not immediate weightbearing with a 1-inch heel lift. Augmented Krackow repairs appear to be the only repair method in this study to be able to withstand early range of motion and weightbearing with a 1-inch heel lift. It would not be advisable to start unprotected weightbearing in any of these groups.

This study is inherently limited by the use of cadaveric specimens, especially because our model used a clean laceration as opposed to the “mop ends” typically seen in Achilles tendon ruptures. However, we believe that this accentuates the differences between techniques even further. Because the cross-stitch epitendinous weave grasps the normal tendon 2.5 cm away from the “mop ends” site, this augmentation would tend to be less affected by the “mop ends” typically seen in the clinical setting. The core sutures that are put in via both the percutaneous method and Krackow method would be more likely affected by the “mop ends” due to the poor nature of the tissue at the tear site. Thus, we initially expected that because we were studying this in normal tendon tissue, it would have been harder to show a difference.

[‡]References 2, 7, 12, 13, 15, 20, 21, 24, 26, 28, 30.

In conclusion, epitendinous cross-stitch weave augmentation of Achilles tendon repairs significantly increased repair strength and gap resistance. The forces the Achilles tendon are exposed to during early motion therapy protocols and ambulation in a Cam Walker may be sufficient to cause gapping and failure in percutaneous and nonaugmented Krackow repairs but not in augmented repairs.

REFERENCES

- Akizuki KH, Gartman EJ, Nisonson B, Ben-Avi S, McHugh MP. The relative stress on the Achilles tendon during ambulation in an ankle immobiliser: implications for rehabilitation after Achilles tendon repair. *Br J Sports Med*. 2001;35:329-333.
- Aoki M, Ogiwara N, Ohta T, Nabeta Y. Early active motion and weight-bearing after cross-stitch achilles tendon repair. *Am J Sports Med*. 1998;26:794-800.
- Carmont MR, Maffulli N. Modified percutaneous repair of ruptured Achilles tendon. *Knee Surg Sports Traumatol Arthrosc*. 2008;16(2):199-203.
- Ceccarelli F, Berti L, Giuriati L, Romagnoli M, Giannini S. Percutaneous and minimally invasive techniques of Achilles tendon repair. *Clin Orthop Relat Res*. 2007;458:188-193.
- Citak M, Knobloch K, Albrecht K, Krettek C, Hufner T. Anatomy of the sural nerve in a computer-assisted model: implications for surgical minimal-invasive Achilles tendon repair. *Br J Sports Med*. 2007;41(7):456-458.
- Cretnik A, Kosanovic M, Smrkolj V. Percutaneous versus open repair of the ruptured Achilles tendon: a comparative study. *Am J Sports Med*. 2005;33:1369-1379.
- Fernandez-Fairen M, Gimeno C. Augmented repair of Achilles tendon ruptures. *Am J Sports Med*. 1997;25:177-181.
- Finni T, Komi PV, Lukkariniemi J. Achilles tendon loading during walking: application of a novel optic fiber technique. *Eur J Appl Physiol Occup Physiol*. 1998;77(3):289-291.
- Gigante A, Moschini A, Verdenelli A, Del Torto M, Ulisse S, de Palma L. Open versus percutaneous repair in the treatment of acute Achilles tendon rupture: a randomized prospective study. *Knee Surg Sports Traumatol Arthrosc*. 2008;16(2):204-209.
- Haji A, Sahai A, Symes A, Vyas JK. Percutaneous versus open tendo Achillis repair. *Foot Ankle Int*. 2004;25(4):215-218.
- Hockenbury RT, Johns JC. A biomechanical in vitro comparison of open versus percutaneous repair of tendon Achilles. *Foot Ankle*. 1990;11(2):67-72.
- Jaakkola JI, Hutton WC, Beskin JL, Lee GP. Achilles tendon rupture repair: biomechanical comparison of the triple bundle technique versus the Krakow locking loop technique. *Foot Ankle Int*. 2000;21:14-17.
- Jarvinen TA, Kannus P, Paavola M, Jarvinen TL, Jozsa L, Jarvinen M. Achilles tendon injuries. *Curr Opin Rheumatol*. 2001;13:150-155.
- Kangas J, Pajala A, Ohtonen P, Leppilahti J. Achilles tendon elongation after rupture repair: a randomized comparison of 2 postoperative regimens. *Am J Sports Med*. 2007;35:59-64.
- Krackow KA, Thomas SC, Jones LC. Ligament-tendon fixation: analysis of a new stitch and comparison with standard techniques. *Orthopedics*. 1988;11:909-917.
- Lee SJ, Goldsmith S, Nicholas SJ, McHugh MP, Kremenich IJ, Ben-Avi S. Optimizing Achilles tendon repair: effect of epitendinous suture augmentation on the strength of Achilles tendon repairs. *Foot Ankle Int*. 2008;29(4):427-432.
- Lim J, Dalal R, Waseem M. Percutaneous vs. open repair of the ruptures Achilles tendon: a prospective randomized controlled study. *Foot Ankle Int*. 2001;22(7):559-568.
- Maes R, Copin G, Averous C. Is percutaneous repair of the Achilles tendon a safe technique? A study of 124 cases. *Acta Orthop Belg*. 2006;72(2):179-183.
- Majewski M, Rohrbach M, Czaja S, Ochsner P. Avoiding sural nerve injuries during percutaneous Achilles tendon repair. *Am J Sports Med*. 2006;34(5):793-798.
- Mandelbaum BR, Myerson MS, Forster R. Achilles tendon ruptures: a new method of repair, early range of motion, and functional rehabilitation. *Am J Sports Med*. 1995;23:392-395.
- Moller M, Lind K, Movin T, Karlsson J. Calf muscle function after Achilles tendon rupture: a prospective, randomised study comparing surgical and non-surgical treatment. *Scand J Med Sci Sports*. 2002;12:9-16.
- Mullaney MJ, McHugh MP, Tyler TF, Nicholas SJ, Lee SJ. Weakness in end-range plantar flexion after Achilles tendon repair. *Am J Sports Med*. 2006;34:1120-1125.
- Orishimo KF, Burstein G, Mullaney MJ, et al. Effect of knee flexion angle on achilles tendon force during passive dorsiflexion. *J Foot Ankle Surg*. 2008;47(1):34-39.
- Rebeccato A, Santini S, Salmaso G, Nogarin L. Repair of the Achilles tendon rupture: a functional comparison of three surgical techniques. *J Foot Ankle Surg*. 2001;40:188-194.
- Soldatis JJ, Goodfellow DB, Wilber JH. End-to-end operative repair of Achilles tendon rupture. *Am J Sports Med*. 1997;25:90-95.
- Solveborn SA, Moberg A. Immediate free ankle motion after surgical repair of acute Achilles tendon ruptures. *Am J Sports Med*. 1994;22:607-610.
- Strauss EJ, Ishak C, Jazrawi L, Sherman O, Rosen J. Operative treatment of acute Achilles tendon ruptures: an institutional review of clinical outcomes. *Injury*. 2007;38(7):832-838.
- Watson TW, Jurist KA, Yang KH, Shen KL. The strength of Achilles tendon repair: an in vitro study of the biomechanical behavior in human cadaver tendons. *Foot Ankle Int*. 1995;16:191-195.
- Webb JM, Bannister GC. Percutaneous repair of the ruptured tendo Achillis. *J Bone Joint Surg Br*. 1999;81(5):877-880.
- Zell RA, Santoro VM. Augmented repair of acute Achilles tendon ruptures. *Foot Ankle Int*. 2000;21:469-474.